



Jessica Prasad

MBBS(Hons), is a surgical registrar, The Alfred Hospital, Melbourne, Victoria. jessicaprasad@mac.com

Vincent C Cousins

BMedSci, MBBS, FRACS, is Clinical Associate Professor, Monash University Department of Surgery, and an otologist-neurotologist, The Alfred Hospital, Melbourne, Victoria.



Asymmetrical hearing loss

Background

General practitioners are usually the first point of contact for patients with hearing loss. Asymmetrical sensorineural hearing loss can be a symptom of a wide range of diseases. A correct diagnosis is essential for appropriate treatment and limitation of the progression of hearing loss.

Objective

This article provides an outline for an approach to a patient presenting with asymmetrical sensorineural hearing loss, and also provides a brief summary of four disease processes which may present with asymmetrical hearing loss.

Discussion

Asymmetrical sensorineural hearing loss may be secondary to the process of aging or simply be related to excessive noise exposure. It can however, be the only presenting symptom of a vestibular schwannoma or an intracranial tumour. A high level of clinical suspicion is required to ensure that these pathologies are not missed.

■ **Hearing loss is the most prevalent sensory deficit reported by patients. Ten to 20% of Australians have some hearing impairment and approximately 50% of those over 65 years of age are hearing impaired. In 2005–2006, 2.6% of all general practice encounters in Australia were for ear symptoms with an additional 0.8% for vertigo and dizziness.¹ Hearing loss can be conductive, sensorineural or mixed. The most common type of hearing impairment in adults is sensorineural.²**

Sensorineural hearing loss (SNHL) indicates defects in either the cochlea or in the neural transmission to the central nervous system. *Table 1* demonstrates the wide range of possible aetiologies of SNHL. The more common causes of SNHL include presbycusis, noise induced hearing loss, Meniere disease, drug induced (ie. aminoglycosides) and infectious causes.

Asymmetrical sensorineural hearing loss (ASNHL) is defined as binaural difference in bone conduction thresholds of >10 dB at two consecutive frequencies or >15 dB at one frequency (0.25–8.0 kHz)³ (*Figure 1*). Poorer speech perception will often accompany poorer hearing and may be the reason for the patient's presentation. A difference of >15% in the maximum speech discrimination score is also significant.

An approach to patient presenting with ASNHL

Asymmetrical sensorineural hearing loss may occur as a result of the common causes of bilateral sensorineural hearing loss such as age related or noise related hearing loss. However, ASNHL may also be:

- the only presenting symptom of a vestibular schwannoma or an intracranial tumour
- an indicator of another serious underlying pathological process such as an immune disorder or demyelinating disease, or
- associated with conditions such as idiopathic sudden SNHL or Meniere disease which may require specialist referral.



Dual pathology is not uncommon in the causation of SNHL, and it is the asymmetry of the loss that may indicate an additional pathological process in the worse hearing ear. Therefore, the management of a patient with ASNHL requires a high level of clinical suspicion to ensure that these pathologies are not missed.

Unilateral tinnitus, with or without associated hearing loss, has the same diagnostic implications as ASNHL.

A detailed history can give valuable clues to the aetiology of the hearing loss. It is important to establish:

- the pattern of the hearing loss (unilateral or bilateral symptoms, progressive or stepwise, sudden or gradual in onset)
- associated symptoms such as tinnitus, aural fullness, vertigo, imbalance, otalgia and otorrhoea
- history of previous ear infections, noise exposure, otic barotrauma or ear surgery
- history of trauma to the ear or head
- previous intracranial surgery
- general health (conditions such as cerebrovascular disease, diabetes, other metabolic and autoimmune disorders can affect hearing)
- family history of hearing loss or ear related tumours
- use of medications such as antibiotics (especially aminoglycosides), antimalarial drugs, anti-inflammatory agents (nonsteroidal anti-inflammatory agents [NSAIDs], salicylates), chemotherapeutic agents and diuretics.

Clinical examination

The clinical examination includes examination of:

- the auricles – skin lesions, pre-auricular sinuses, oedema, erythema, tragal tenderness
- external auditory canals – mass lesion, discharge
- tympanic membranes – colour, thickness, scarring, effusion, perforations
- head and neck
- cranial nerves, and
- postnasal space.

Gross testing of hearing can be carried out using whisper tests. Tuning fork tests generally allow the physician to determine whether there is a conductive component to the hearing loss (*Table 2*).

All patients with ASNHL require investigations including audiology and detailed diagnostic imaging (usually magnetic resonance imaging [MRI]) to determine aetiology. In some cases various blood tests will assist. The clinical examination and history may often provide little help in differentiating patients with more common minor ear conditions from those with significant or sinister diagnosis. Cranial nerve palsies on examination are a worrying sign. All patients with ASNHL require specialist ear, nose and throat (ENT) referral and assessment due to the complex nature of the involved pathologies. It is preferable for this to happen within 6 weeks; but sooner if there are other associated neurological symptoms or signs.

Table 1. Examples of pathologies associated with SNHL

Hereditary and developmental	<ul style="list-style-type: none"> • Syndromic (1/3) <ul style="list-style-type: none"> – Usher syndrome – Pendred syndrome – Alport syndrome • Nonsyndromic (2/3) <ul style="list-style-type: none"> – autosomal dominant inheritance – autosomal recessive inheritance – x lined or maternal mitochondrial – cochlear otosclerosis • Inner ear anomalies <ul style="list-style-type: none"> – large vestibular aqueduct • Cochlea anomalies <ul style="list-style-type: none"> – Mondini
Infection*	<ul style="list-style-type: none"> • Meningitis, mumps, rubella, syphilis • Other viral infections
Immune disorders	<ul style="list-style-type: none"> • Systemic lupus erythromatosus • Rheumatoid arthritis • Polymyositis • Ulcerative colitis • Scleroderma • HIV
Neurological	<ul style="list-style-type: none"> • Multiple sclerosis • Cerebral ischaemia/stroke • Migraine
Neoplasms*	<ul style="list-style-type: none"> • Benign <ul style="list-style-type: none"> • Vestibular schwannomas (acoustic neuroma) • Meningiomas/other • Malignant <ul style="list-style-type: none"> • Local primary tumours • Metastatic lesions
Ototoxins*	<ul style="list-style-type: none"> • Aminoglycosides • Loop diuretics • Quinine • Chemotherapy agents (eg. cisplatin) • NSAIDs
Systemic	<ul style="list-style-type: none"> • Paget disease • Diabetes mellitus • Hypertriglyceridemia/hypercholesterolemia
Trauma*	<ul style="list-style-type: none"> • Noise induced • Acoustic trauma • Head injury • Previous cranial/ear surgery
Vascular/haematological	<ul style="list-style-type: none"> • Coagulopathies • Leukaemia
Idiopathic*	<ul style="list-style-type: none"> • Presbycusis • Meniere disease • Idiopathic sudden sensorineural hearing loss
* Indicates a more common/important condition	



Investigation may lead to a means of treating or limiting the hearing loss, such as in Meniere disease. It may indicate the presence of lesions that need treatment such as large cerebellopontine angle tumours. It may simply provide a diagnosis of cause and explanation to the patient which may not be specifically treatable, or which may have implications for other family members where an inherited cause is identified.

Audiology

Routine audiology testing includes pure tone audiometry (PTA), speech discrimination tests and impedance tympanometry. Evoked potential audiometry, which includes auditory brainstem response and electrocochleography (ECoG), may be used in particular circumstances.

Pure tone audiometry is a measure of hearing levels by air and bone conduction using pure tone stimuli (at 250, 500, 1000, 2000, 4000 and 8000 Hz) at selected intensities. Speech audiometry utilises spoken voice as a sound stimulus at selected intensities.

The speech discrimination score is calculated as the highest percentage of phonemes or word parts repeated correctly when presented at 40 dB or more above the average response levels obtained on the pure tone air conduction test. A disproportionate loss of speech discrimination compared to PTA results may be indicative of a problem with the cochlear nerve (retrocochlear pathology).

Imaging

A finding of ASNHL will generally necessitate the use MRI of the inner ear and brain to exclude retrocochlear pathology such as a vestibular schwannoma, meningioma or other intracranial tumours.

Signs of demyelinating lesions of central nervous system may also be identified with this technique. The use of gadolinium contrast increases the sensitivity of this study. Computerised tomography (CT) scanning may be used if inner ear pathology or a developmental anomaly such as an inner ear dysplasia or large vestibular aqueduct is suspected. Computerised tomography scanning, preferably with the use of contrast, will also be used if an MRI is contraindicated such as when the patient has implanted electrical devices (cochlear implant, cardiac pacemaker) or a cerebral aneurysm clip.⁴

Magnetic resonance imaging do not attract a Medicare rebate unless ordered by a specialist. If there are concerns about a major space occupying lesion, a contrast enhanced CT scan can be arranged early by the GP first to exclude any lesion >1.5 cm in maximum diameter. If clear, then it is reasonable to wait for ENT assessment.

Serology, haematology, biochemistry

Haematological, biochemical and serological tests may be useful in investigating hearing loss and choice of investigation will be determined by the history and examination findings. These include:

- fluorescent treponemal antibody for syphilis
- fasting blood sugar levels for diabetes
- erythrocyte sedimentation rate, antinuclear antibodies and rheumatoid factor in patients with a suspected immune cause of hearing loss.³

Other specialised investigations such as haemolytic component and antiheat shock protein 70 antibodies^{5,6} are sometimes used in the specialist setting.

An overview of four pathologies, which may present as ANSHL, is presented below.

Noise induced sensorineural hearing loss

Hearing impairment secondary to excessive noise exposure is one of the most common causes of new presentations with sensorineural hearing impairment⁷ and may account for approximately 30–50% of hearing loss presentations. Prolonged or cumulative exposure to noise levels exceeding 75–80 dB such as may occur with loud music, machinery and gun shooting, overwhelms the reparative capacity of the cochlear hair cells and result in permanent hearing loss.⁸ The pattern of hearing loss is usually bilateral and equal but may be asymmetrical, particularly if one ear is preferentially exposed to the noise source, such as with gun shooting.

The diagnosis is indicated by a history of excessive or prolonged noise exposure and an audiogram finding of high frequency SNHL occurring maximally at 3–6 KHz. Other causes of ASNHL will need to be excluded.

The management of noise induced sensorineural hearing loss (NISNHL) is primarily preventive with education concerning avoidance of noisy environments and use of appropriate protective equipment such as ear plugs or ear muffs. Noise that precludes one hearing another speak is likely to be >80 dB in intensity. Some machinery is labelled with intensity data as a guide.

Figure 1A, B. Audiograms showing mild (A) and severe (B) asymmetrical sensorineural hearing loss

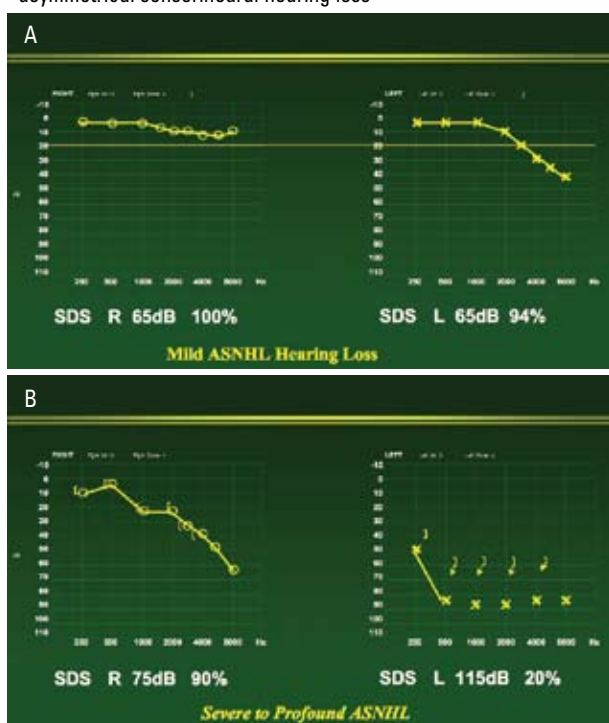


Table 2. Tuning fork tests

The Rinne test compares air conduction (AC) with bone conduction (BC) using a 256 Hz or 512 Hz tuning fork which is struck and placed on the mastoid process. When the patient can no longer hear the sound conducted via the bone, the fork is moved to beside the external auditory canal (EAC). AC is greater than BC (AC>BC) if the patient still can hear the sound at the EAC. This is called a positive Rinne test and is consistent with normal hearing or ipsilateral SNHL. A negative Rinne test (BC>AC) indicates ipsilateral conductive hearing loss (CHL) or profound SNHL with crossover

The Weber test utilises a 512 Hz tuning fork. The resonating fork is placed on the vertex and the patient is asked to identify the ear where the sound is heard louder. In a conductive loss, the Weber lateralises to the affected ear. In SNHL, the sound lateralises to the better hearing ear. Central perception indicates symmetrical hearing

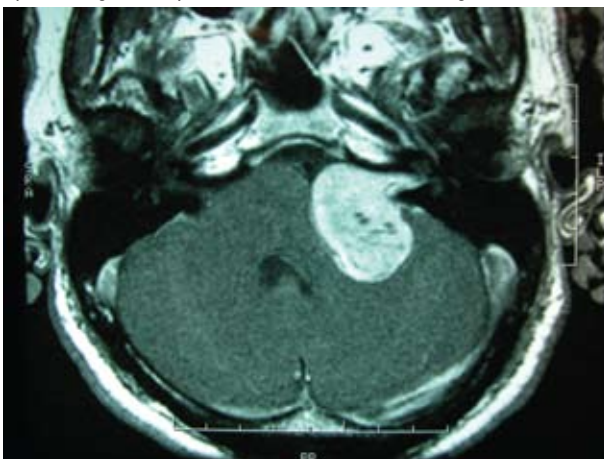
	Weber test	Rinne test left ear	Rinne test right ear
Normal hearing	Central	Positive (AC>BC)	Positive (AC>BC)
CHL left ear	Localises to left	Negative (BC>AC)	Positive (AC>BC)
CHL right ear	Localises to right	Positive (AC>BC)	Negative (BC>AC)
Symmetrical SNHL	Central		
ASNHL left ear affected	Localises to right	Positive (negative if profound SNHL on left)	Positive
ASNHL right ear affected	Localises to left	Positive	Positive (negative if profound SNHL on right)

Once NISNHL has been diagnosed, the use of hearing aids may be necessary to aid communication. Affected subjects should also be advised to protect their ears from all noxious influences, including further noise exposure.

Vestibular schwannoma

Vestibular schwannoma (acoustic neuroma) is a benign tumour arising from the Schwann cells in the vestibular portion of eighth cranial nerve. It usually begins growing in the internal auditory canal and extends into the cerebellopontine angle of the posterior cranial fossa with time. The clinical incidence rate is approximately 1 per 100 000 per year and the incidence may have increased in recent years increase due to the increased use of MRI.⁹ This tumour comprises greater than 85% of all cerebellopontine angle tumours.

Figure 2. MRI of left sided vestibular schwannoma in patient presenting with asymmetrical sensorineural hearing loss



The incidence of vestibular schwannoma is about 2% in all patients with ASNHL.¹⁰

The mean age of diagnosis is in the mid 40s. It is uncommon in younger patients and may be associated with the rare condition of neurofibromatosis type 2 in these patients.

Presentation is usually with asymmetrical hearing loss. Typically hearing loss is gradual, but sudden onset of hearing loss has been found in 12–16% of affected patients.^{11,12} Patients may also have unilateral tinnitus, vertigo and balance disturbance. Facial and trigeminal nerve function may also be altered.⁸

Examination findings are generally few. Tuning fork tests should be performed (*Table 2*). Facial numbness, especially a reduced corneal reflex, and facial weakness may be seen with larger tumours.

Audiogram findings include some pattern of ASNHL and decreased speech discrimination scores. Vestibular function tests may indicate reduced responses. Auditory brainstem responses are frequently abnormal, however they are affected in many other conditions leading to high false positive and false negative rates.^{13,14} Magnetic resonance imaging with gadolinium is sensitive for tumours from 2 mm in size and is used in most patients presenting with ASNHL to ensure that vestibular schwannomas are diagnosed (*Figure 2*).

High resolution CT scanning of the temporal bones provides excellent middle ear cleft and inner ear detail. It does however have limitations in assessing intracranial tumours <1.5 cm. A contrast enhanced MRI should be performed when significant pathology is suspected.⁴

Management of the tumour depends on tumour size, patient symptoms, preference and comorbidities, and availability of treatment facilities and expertise. Management options include observation, radiation or surgery.



Close observation using serial MRI can be an option for small tumours or patients with significant medical comorbidities. Treatment may then be undertaken if there is tumour growth or increasing patient symptoms. Microsurgical excision of the tumour is still regarded as the gold standard of treatment. This may entail sacrifice of hearing (translabyrinthine approach) in large tumours or where there is poor pre-operative hearing. Hearing preservation approaches (middle and posterior cranial fossa approaches) may be used in smaller tumours with good presenting hearing. Stereotactic radiation therapy can be used for tumours up to 3 cm in maximum dimension, particularly in the elderly and the infirm. The aim of surgery is total tumour removal while minimising morbidity. Radiation is used to halt tumour growth. All treatment is aimed at limiting morbidity and preventing mortality caused by tumour growth. Cure rates range 90–99% in various series for either modality of treatment.^{9,15,16}

Idiopathic sudden sensorineural hearing loss

Idiopathic sudden sensorineural hearing loss (ISSNHL) of unknown aetiology is a loss of significant hearing (>30 dB in at least three adjacent frequencies) that occurs over <72 hours. The incidence is 8–15 per 100 000 per year.¹⁷ Proposed causes include viral inflammation of the cochlear nerve or inner ear, vascular interruption, rupture of intralabyrinthine membranes and autoimmune diseases. The average age of onset is 40–50 years. Hearing loss is unilateral in 95–100% of patients. Bilateral loss tends to occur in an older population with lower recovery rates.^{9,18} Overall recovery rates are 50–65% with a high rate of spontaneous recovery.

A diagnosis of ISSNHL necessitates exclusion of mass lesions and other discrete conditions causing ASNHL. However, the acute onset of hearing loss and pattern seen on audiogram findings are nonspecific for any particular diagnosis.

Treatment is controversial as the aetiology remains obscure. Oral steroids are used frequently, however evidence for their effectiveness is lacking.¹⁹ In the acute setting, it is reasonable to institute a 1 week reducing course of prednisolone if there are no medical contraindications. All patients will need ENT review and MRI, but a good quality CT scan can be done early to exclude a major space occupying lesion. If the hearing loss is in the better hearing or only hearing ear, referral should be made on the day of presentation.

There is some evidence that steroids injected into the middle ear may have a role in the treatment of ISSNHL,^{20–24} particularly if oral steroid treatment has failed. Hyperbaric oxygen may improve hearing in early presentation ISSNHL.²⁵ Vasodilators and antivirals have also been used, however evidence of efficacy is lacking. Patients may need hearing aids and other rehabilitation where there is inadequate recovery.

Meniere disease

This is a disorder characterised by recurrent episodes of spontaneous vertigo associated with fluctuating hearing loss and tinnitus, often accompanied by a sense of aural fullness. The incidence is 10–20 per 100 000²⁶ per year²⁷ and most commonly

presents at 40–60 years of age. The aetiology of the disease is not fully understood. The disorder is thought to be related to raised endolymph volume in the membranous labyrinth of the inner ear, termed 'endolymphatic hydrops'. Hearing loss is sensorineural, low frequency and usually unilateral. Bilateral disease has been reported in various series as having a prevalence of 2–78% and development of bilateral disease may occur in time.²⁸ With disease progression, high frequency hearing loss occurs as well and the patient is left with a moderate to severe SNHL affecting all frequencies, indicated by a flat pure tone audiogram

The diagnostic guidelines developed by the American Academy of Otolaryngology²⁹ stipulate that at least two spontaneous episodes of rotational vertigo lasting at least 20 minutes, audiological confirmation of sensorineural hearing loss and tinnitus, or perception of aural fullness are required for a diagnosis.

As these patients present with ASNHL, most have imaging studies to exclude retrocochlear pathology. Electrocochleography and vestibular function tests are also usually performed.

Management is challenging due to incomplete understanding of the disease process and the paroxysmal nature of the symptoms. Treatment aims to reduce the frequency and severity of vertiginous attacks, and ameliorate or abort hearing loss and tinnitus. Medical treatments, which are usually first line treatment, include a low salt diet, diuretics (thiazides) and a betahistine. In patients with symptoms and signs suggesting Meniere disease, it is very reasonable for the GP to institute these medical measures, particularly if there is delay in availability of ENT assessment. The efficacies of these treatments have not been proven.^{27,30}

Pressure pump therapy, surgical modalities including endolymphatic sac surgery, labyrinthectomy and vestibular nerve section, and chemical ablation using intratympanic gentamicin^{31,32} are treatments used to alleviate vertigo in the 15–20% of patients who have failed medical treatment. Intratympanic steroids have been used for treatment of SNHL associated with Meniere disease with variable success.^{33–36}

Summary of important points

- ASNHL can be a presenting symptom of a range of disease processes.
- Thorough history and examination are invaluable in directing further investigations.
- The use of tuning forks can differentiate SNHL from CHL.
- All ASNHL must be investigated.
- Important conditions not to be missed include vestibular schwannoma and other CPA tumours.

Conflict of interest: none declared.

References

1. Britt H, Miller GC, Charles J, et al. General practice activity in Australia 2005–06. Canberra: Australian Institute of Health and Welfare, 2007. Available at www.aihw.gov.au/publications/index.cfm/title/10377/ [Accessed December 2007].
2. Angeli SI, Yan D, Telischi F, et al. Etiologic diagnosis of sensorineural hearing loss in adults. *Otolaryngol Head Neck Surg* 2005;132:890–5.

3. Sabini P, Sclafani AP. Efficacy of serologic testing in asymmetrical sensorineural hearing loss. *Otolaryngol Head Neck Surg* 2000;122:469–76.
4. Cousins VC. Lateral skull base surgery: a complicated pursuit? *J Laryngol Otol* 2007. Published online ahead of print.
5. Rauch SD, San Martin JE, Moscicki RA, Bloch KJ. Serum antibodies against heat shock protein 70 in Meniere's disease. *Am J Otol* 1995;16:648–52.
6. Bonaguri C, Orsoni JG, Zavota L, et al. Anti-68 kDa antibodies in autoimmune sensorineural hearing loss: are these autoantibodies really a diagnostic tool? *Autoimmunity* 2007;40:73–8.
7. Miller MH. Hearing conservation in industry. *Current Op Otol Head Neck Surg* 1998;6:352–7.
8. Miller MH, Schein JD. Selected complex auditory disorders. *J Rehab Research Develop* 2005;42:1–8.
9. Myrseth E, Pedersen PH, Moller P, Lund-Johansen M. Treatment of vestibular schwannomas. Why, when and how? *Acta Neurochir* 2007;49:647–60.
10. Urban SL, Benninger MS, Gibbens ND. Asymmetrical sensorineural hearing loss in a community-based population. *Otolaryngol Head Neck Surg* 1999;120:809–14.
11. Matthies C, Samii M. Management of 1000 vestibular schwannomas (acoustic neuroma): clinical presentation. *Neurosurgery* 1997;40:1–10.
12. Moffat DA, Baguley DM, Blumenthal H, Irving RM, Hardy DG. Sudden deafness in vestibular schwannoma. *J Laryngol Otol* 1994;108:116–9.
13. Rupa V, Job A, George M, Rajshekar V. Cost-effective initial screening for vestibular schwannoma: Auditory brainstem response or magnetic resonance imaging? *Otolaryngol Head Neck Surg* 2003;128:823–8.
14. Gordon ML, Cohen NL. Efficacy of Auditory Brainstem Response as a screening test for small acoustic neuromas. *Am J Otol* 1995;16:136–9.
15. Samii M, Matthies C. Management of 1000 vestibular schwannomas (acoustic neuromas): surgical management and results with an emphasis on complications and how to avoid them. *Neurosurgery* 1997;40:11–23.
16. Hempel JM, Hempel E, Wowra B, Schichor C, Muacevic A, Riederer A. Functional Outcome after gamma knife treatment in vestibular schwannoma. *Eur Arch Oto Rhino Laryngol* 2006;263:714–8.
17. Agarwal L, Pothier DD. Vasodilators and vasoactive substances for idiopathic sudden sensorineural hearing loss. *Cochrane Database Syst Rev* 2006;4:CD003422.
18. Oh J, Park K, Lee S, Shin Y, Choung Y. Bilateral versus unilateral sudden sensorineural hearing loss. *Otolaryngol Head Neck Surg* 2007;136:87–91.
19. Wei BPC, Mubiru S, O'Leary S. Steroids for idiopathic sudden sensorineural hearing loss. *Cochrane Database Syst Rev* 2006;1:CD 003998.
20. Haynes DS, O'Malley M, Cohen S, Watford K, Labadie RF. Intratympanic dexamethasone for sudden sensorineural hearing loss after failure of systemic therapy. *Laryngoscope* 2007;117:3–15.
21. Xenellis J, Papadimitrou N, Nikolopolous T, et al. Intratympanic steroid treatment in idiopathic sudden sensorineural hearing loss: a control study. *Otolaryngol Head Neck Surg* 2006;134:940–5.
22. Ahn JH, Yoo MH, Yoon TH, Chung JW. Can intratympanic dexamethasone added to systemic steroids improve hearing outcome in patients with sudden deafness. *Laryngoscope* 2007;Nov 6 Epublished ahead of print.
23. Kilic R, Safak MA, Oguz H, et al. Intratympanic methylprednisolone for sudden sensorineural hearing loss. *Otol Neurotol* 2007;28:312–6.
24. Plaza G, Herraiz C. Intratympanic steroids for treatment of sudden hearing loss after failure of intravenous therapy. *Otolaryngol Head Neck Surg* 2007;137:71–8.
25. Bennett MH, Kertesz T, Yeung P. Hyperbaric oxygen for idiopathic sudden sensorineural hearing loss and tinnitus. *Cochrane Database Syst Rev* 2007;1:CD004739.
26. Neuhauser HK. Epidemiology of vertigo. *Curr Opin Neurol* 2007;20:40–6.
27. Thirlwall AS, Kundu S. Diuretics for Meniere's disease or syndrome. *Cochrane Database Syst Rev* 2006;3:CD003599.
28. House JW, Doherty JK, Fisher LM, Derebery MJ, Berliner KI. Meniere's disease: prevalence of contralateral ear involvement. *Otol Neurotol* 2006;27:355–61.
29. Monsell EM, Balkany TA, Gates GA, Goldenberg RA, Meyerhoff WL, House JW. Committee on hearing and equilibrium. Guidelines for diagnosis and evaluation of therapy in Meniere's disease. *Otolaryngol Head Neck Surg* 1995;113:181–5.
30. James AL, Burton MJ. Betahistine for Meniere's disease or syndrome. *Cochrane Database Syst Rev* 2001;1:CD001873.
31. Flanagan S, Mukherjee P, Tonkin J. Outcomes in the use of intra-tympanic gentamicin in the treatment of Meniere's disease. *J Laryngol Otol* 2006;120:98–102.
32. Lange G, Maurer J, Mann W. Long term results after interval therapy with intratympanic gentamicin for Meniere's disease. *Laryngoscope* 2004;114:102–5.
33. Light JP, Silverstein H. Transtympanic perfusion: indications and limitations. *Current Op Otol Head Neck Surg* 2004;12:378–83.
34. Arriaga MA, Goldman S. Hearing results of intratympanic steroid treatment of endolymphatic hydrops. *Laryngoscope* 1998;108:1682–5.
35. Garduno-Anaya MA, De Toledo HC, Hinojosa-Gonzalez R, pane-Pianese C, Rios-Castaneda LC. Dexamethasone inner ear perfusion by intratympanic injection in unilateral Meniere's disease: a two-year prospective, placebo-controlled, double-blind, randomised trial. *Otolaryngol Head Neck Surg* 2005;133:285–94.
36. Selivanova OA, Gouveris H, Victor A, Amedee RG, Mann W. Intratympanic dexamethasone and hyaluronic acid in patients with low-frequency and Meniere's-associated sudden sensorineural hearing loss. *Otol Neurotol* 2005;26:890–5.